

RESENTING CLINICAL SIGNS

History: History of mildly depressed LV systolic function and rare VPCs. Taurine WNL. Receiving pimobendan 7.5 mg BID and Fortekor 20 mg SID.

DATE

9/13/21

ECHOCARDIOGRAPHIC FINDINGS

2D, M-mode, and Doppler study. This exam is compared to the one performed 4/14/21.

PERFORMED BY:

Dr. Brian Barnes

INTERPRETED BY

Keith Blass, DVM,
MS, DACVIM
(Cardiology)

Left atrial size is normal. The mitral valve appears normal, though mild mitral regurgitation is present. The left ventricular diastolic dimension is normal. Left ventricular systolic function is mildly depressed. The aorta and aortic valve are normal. Right atrial and right ventricular dimensions are normal. The tricuspid appears normal, though trace tricuspid regurgitation is present. The pulmonary artery and pulmonic valve appear normal, though trace pulmonic insufficiency is present. No pericardial effusion or cardiac masses are seen.

ECG during echo: Sinus arrhythmia

PATIENT

Roscoe Robertson

LA - 35.6 mm (prev. 39.0 mm)
LVIDd - 35.4 mm (prev. 43.5 mm)
LVIDs - 25.6 mm (prev. 33.2 mm)
FS - 27.7% (prev. 23.7%)
LVOT - 1.18 m/s (prev. 1.09 m/s)
RVOT - 0.84 m/s (prev. 0.88 m/s)
TR - 2.40 m/s

SPECIES

Canine

ASSESSMENT/RECOMMENDATIONS

This examination demonstrates some improvement in Roscoe's left ventricular systolic function over the past 5 months, as his function now measures just within the normal reference interval, though it's difficult to say whether this improvement is due to the medications Roscoe is receiving or whether there was a transient decrease in function that resolved on its own. In either case, Roscoe's current risk for the development of clinical signs of low cardiac output appears to be low, as is his risk for the development of congestive heart failure.

BREED

Staffordshire Terrier

SEX

No VPCs were seen in today's ECG.

MN

No change in therapy is recommended at this time.

AGE

A recheck echocardiogram and ECG are recommended in 9 months, sooner if new clinical signs compatible with cardiac dysfunction develop.

8 y

WEIGHT

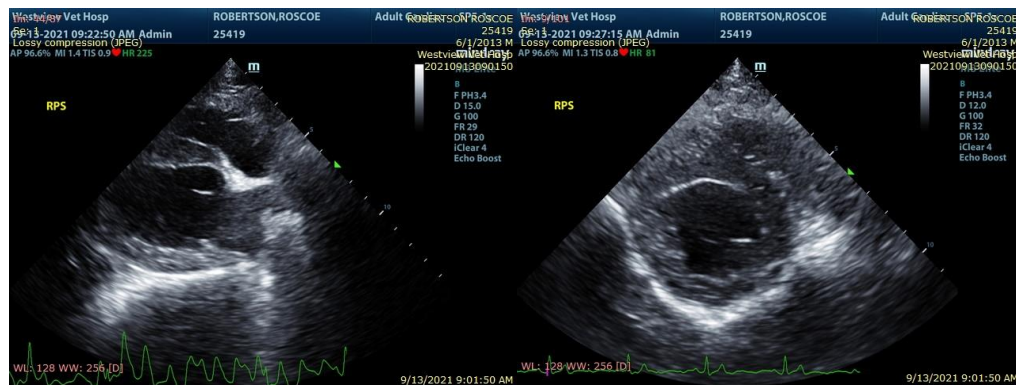
28.8 kg

HOSPITAL NAME

Westview VH

REFERRING VET

Dr. Barnes





DATE

9/13/21

The information and recommendations provided are based on the images presented by the referring veterinarian. No evaluation can be communicated regarding pathology that was not visible in the image/video clips provided.

Thank you for this referral. If the clinical or image interpretation does not parallel your findings or if I can be of any further assistance please contact me.

PERFORMED BY:

Dr. Brian Barnes

Keith Blass, DVM, MS, DACVIM (Cardiology)

KeithBlass@gmail.com

631-804-5754

INTERPRETED BY

Keith Blass, DVM,
MS, DACVIM
(Cardiology)

PATIENT

Roscoe Robertson

SPECIES

Canine

BREED

Staffordshire Terrier

SEX

MN

AGE

8 y

WEIGHT

28.8 kg

HOSPITAL NAME

Westview VH

REFERRING VET

Dr. Barnes